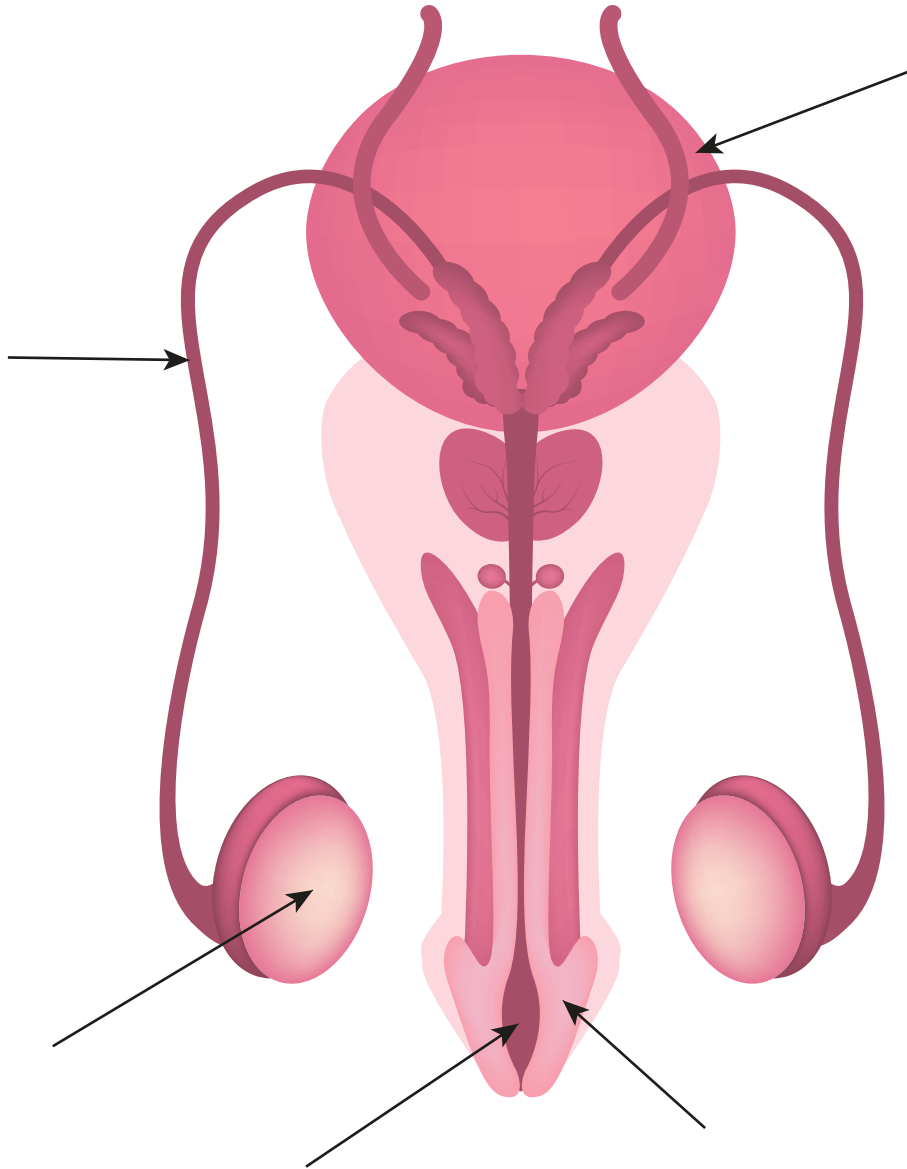


Male internal reproductive organ



Penis

Bladder

Testicle

Sperm duct

Urethra